



PATIENT PRESENTING CLINICAL SIGNS

Buster Powers

History: History seizures. History heart murmur. Presently doing well at home with a good appetite and normal activity level. Occasional cough secondary to tracheal collapse. On exam: NSR, grade II/VI murmur with PMI left apical area PSS lung fields clear coughs easily with minimal tracheal pressure, mm pink, moist, CRT<2. Current medications: 1) Phenobarbital 30mg 1/2 tab twice a day 2) Diphenoxylate with atropine 2.5mg 1/2-tab three times a day 3) Levetiracetam/keppra 500mg 1/4 tab twice a day *Sedated with propofol for study.

SPECIES

Canine

BREED ECHOCARDIOGRAM FINDINGS

Chihuahua

2D, m-mode, color flow and Doppler imaging is available.

Left ventricle: The LV diameter is normal with adequate myocardial function. LV wall thicknesses are normal.

SEX

Male Neutered

Left atrium: The left atrium is normal.

Mitral valve: The mitral valve is diffusely thickened with mild prolapse into the left atrial lumen. Moderate eccentric mitral regurgitation with a normal velocity.

AGE

9 years

Aortic valve/aorta: The aortic valve is normal in morphology and mobility. Normal aortic outflow velocity; laminar flow. No aortic insufficiency.

Right ventricle: Normal right ventricular diameter and morphology indicating no overt evidence of pulmonary arterial hypertension.

Right atrium: Normal RA dimension.

WEIGHT

8.94lbs

Tricuspid valve: The tricuspid valve appears normal with trace tricuspid regurgitation; normal velocity.

Pulmonic valve/pulmonary artery: The pulmonic valve is normal in morphology and mobility. No pulmonic insufficiency. Normal RVOT velocity; laminar flow.

Pericardium/other: No pericardial or pleural effusion noted. No obvious cardiac masses.

Heart rhythm: ECG reveals a sinus rhythm with an average HR of 155bpm.

INTERPRETED BY

Maggie Machen
Lamy, DVM
DACVIM (Cardiology)

2-Dimensional Measurements

Ao diam (cm)	1.2
LA diam (cm)	1.5
LA:Ao (Swe)	1.3
IVS thickness (cm)	0.7
LVID diastole (cm)	1.7
PW thickness (cm)	0.7
LVID systole (cm)	0.8
FS (%)	54

Doppler Measurements

PV Vmax (m/s)	0.5
AoV Vmax (m/s)	0.7
MR Vmax (m/s)	5.0
TR Vmax (m/s)	2.0
TR PG (mmHg)	16

IMAGING

PERFORMED BY

Pamela Harrigan,
RDCS

HOSPITAL NAME

Mass Veterinary Services

REFERRING VET

Dr. Masloski

INTERPRETATION OF THE FINDINGS

The cause of the murmur is chronic degenerative valve disease causing moderate mitral and trace tricuspid regurgitation. Lack of significant left atrial enlargement indicates the current risk for complication is low. No concurrent issues such as pulmonary hypertension are noted in this study.

Assessment of progression in the future will help predict long term prognosis, which is highly variable at this stage (B1).

INVOICE

32011

DATE

7/31/23



PATIENT

Buster Powers

SPECIES

Canine

BREED

Chihuahua

SEX

Male Neutered

AGE

9 years

WEIGHT

8.94lbs

INTERPRETED BY

Maggie Machen Lamy, DVM
DACVIM (Cardiology)

IMAGING PERFORMED BY

Pamela Harrigan, RDCS

HOSPITAL NAME

Mass Veterinary Services

REFERRING VET

Dr. Masloski

INVOICE

32011

DATE

7/31/23

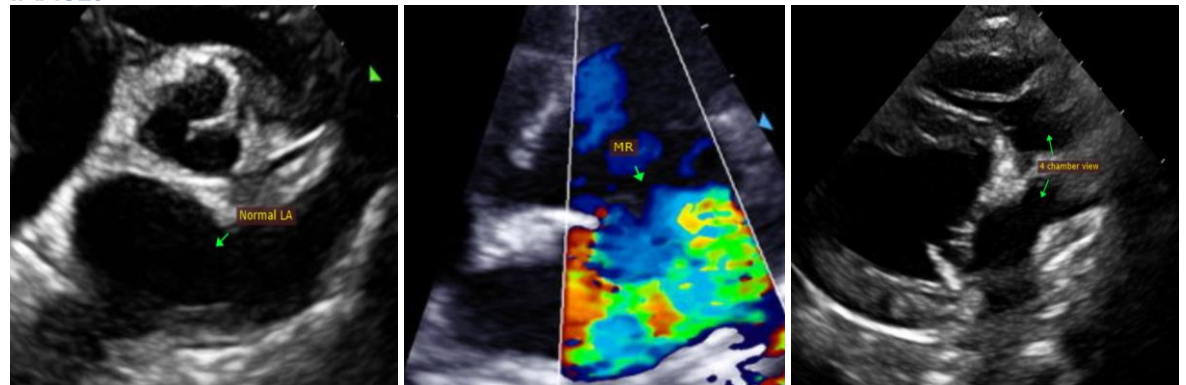
RECOMMENDATIONS

- In a dog without significant left atrial enlargement, no cardiac medications are clearly indicated.
- Omega fatty acid supplementation and mild salt restriction may be of some long-term benefit.
- Anesthetic risk is considered mild if needed. Cardiac protective drug choices (opioid/benzodiazepine premedication, propofol or alfaxalone induction, isoflurane gas) are recommended. Pre-oxygenate for 5-10 minutes prior to induction. Monitor for arrhythmias, hypotension, and hypoxia both intra and post-operatively and intervene as necessary. Mild IV fluid restriction is recommended to avoid fluid overload. Avoid heart rate stimulating drugs such as atropine unless clinically indicated.
- Monitor for development of a cough, labored breathing, exercise intolerance or collapse episodes.

PLAN

- Recommend conservative monitoring with a recheck echocardiogram in 6-12 months, sooner if any development of clinical signs.

IMAGES



The information and recommendations provided are based on the images presented by the referring veterinarian. No evaluation can be communicated regarding pathology that was not visible in the image/video clips provided.

Thank you for this referral. This report was generated using transcription software, and minor dictation errors may be present. If the clinical or image interpretation does not parallel your findings or if I can be of any further assistance, please contact me.

Maggie Machen Lamy, DVM
Diplomate of the American College of Veterinary Internal Medicine (Cardiology)
info@sonopath.com

Echocardiogram performed by: Pamela Harrigan, RDCS
Pet Animal Ultrasound Service (4paus.com)